THE JOURNAL OF PROSTHETIC DENTISTRY

CLINICAL RESEARCH

Retrospective clinical study of monolithic zirconia crowns fabricated with a straightforward completely digital workflow

Lifang Wu, DDS,[a] Zhe Sun, DDS,[b] Jing Zhao, DDS, PhD,[c] and Yuanna Zheng, DDS, PhD[d]

ABSTRACT

Statement of problem. Current computer-aided design and computer-aided manufacturing (CAD-CAM) technology has digitalized some traditional prosthodontic processes, but manual interventions are still needed for both clinical and dental laboratory procedures, and improved digital workflows are required.

Purpose. The purpose of this retrospective clinical study was to develop a straightforward completely digital workflow to fabricate monolithic zirconia crowns and evaluate clinical efficiency and prosthetic outcomes.

Material and methods. Self-glazed zirconia crowns (N=229) were placed in 177 participants between 2016 and 2019 with a completely digital workflow. The extent of clinical adjustment needed for each crown was recorded and then divided into 3 categories: zero adjustment, minimal adjustment, and unacceptable. Color match and marginal adaption were evaluated according to the modified US Public Health Service (USPHS) criteria.

Results. A total of 213 (93.0%) crowns required zero adjustment during clinical evaluation, 11 (4.8%) needed minimal adjustment, and 5 (2.2%) were deemed unacceptable since they could not meet the clinical requirements through adjustment. Except for the unacceptable crowns, the marginal adaption of the remaining 224 crowns was rated as Alfa and the color match as Alfa (91.5%), Bravo (6.3%), and Charlie (2.2%).

Conclusions. The self-glazed monolithic zirconia crowns fabricated with the completely digital workflow provided efficient and satisfactory clinical performance. (J Prosthet Dent 2021;■:■-■)

Contemporary digital prosthodontic workflows that have integrated many advanced technologies are still only partially digital.[1-3] They still involve numerous manual procedures in both the clinical and the laboratory processes, including fabricating an interim crown, characterization, glazing, polishing, and other time-consuming and technically sensitive steps.[4-7] Moreover, the digital design cannot be completely verified in advance, and the definitive restorations may need additional adjustment during clinical evaluation or may even be unacceptable. Excessive adjustment of a fully sintered zirconia restoration could generate serious defects and influence long-term performance.[8,9]

Tidehag and Shen[10] described a completely digital workflow to fabricate monolithic zirconia restorations (Fig. 1). Unlike with the commonly used partial digital workflow, interim restorations are digitally designed and produced, made chairside, and used to verify the accuracy of the digital design. The clinical evaluation of the interim restorations identifies an inappropriate design that can be easily rectified by rescanning the adjusted interim restoration. This procedure is more accurate and straightforward than the traditional technique, which uses a dental articulator and requires an experienced dental laboratory technician.

This completely digital workflow was based on a novel manufacturing technology named the 3D gel deposition process. This process is completely computer controlled and can manufacture more complex geometric shapes with higher accuracy than the conventional subtractive milling process.[11] The shape and size of the milling burs prevent small concave shapes from being accurately milled.[11] In contrast, the additive process stacks nanoscale zirconia colloids of different colors and grain sizes layer by layer to form

This research did not receive any specific grant from funding agencies in the public, commercial, or not-for-profit sectors.
[a]Graduate student, Graduate Prosthodontics, School of Stomatology, Zhejiang Chinese Medical University, Hangzhou, PR China.
[b]Graduate student, Graduate Prosthodontics, School of Stomatology, Zhejiang Chinese Medical University, Hangzhou, PR China.
[c]Attending physician, Department of general dentistry, Stomatological Hospital affiliated to Zhejiang Chinese Medical University, Hangzhou, PR China.
[d]Associate Professor, School of Stomatology, Zhejiang Chinese Medical University, Hangzhou, PR China.

Clinical Implications

Digital technology can replace manual procedures and simplify the production of zirconia crowns to improve the efficiency and precision of definitive restorations. The completely digital workflow for producing monolithic zirconia crowns was efficient, satisfactory, and straightforward.

a monolithic zirconia restoration. The definitive restoration can replicate individual tooth color and the transparency gradient of natural teeth. It also generates an enamel-like smooth surface.[12,13] With the elimination of manual characterization, glazing, grinding, or polishing, this digital workflow can replicate the verified design accurately.

The completely digital workflow has been used to make different types of monolithic zirconia restorations, including crowns, fixed dental prostheses (FDPs), and implant-supported prostheses with satisfactory clinical results.[14-19] The purpose of this retrospective clinical study was to evaluate the effectiveness of this workflow for making monolithic zirconia single crowns and to record its clinical efficiency. The hypothesis was that the monolithic zirconia crowns fabricated with the completely digital workflow would achieve satisfactory clinical performance.

MATERIAL AND METHODS

The clinical records of all patients who had been restored with monolithic zirconia single crowns (Self-glazed zirconia; Erran Tech) with a completely digital workflow from July 2016 to December 2019 in the Department of General Dentistry, Stomatological Hospital affiliated to the Zhejiang Chinese Medical University were screened. The records with complete treatment procedures and evaluation results were eligible for inclusion into this study. All the clinical procedures had been performed by the same prosthodontist (Y.Z.) who had more than 10 years of experience and the same dental laboratory technician with more than 3 years of experience. This study complied with the Helsinki Declaration and was approved by the Institutional Review Board of the Stomatological Hospital Affiliated to the Zhejiang Chinese Medical University (#202000104).

The completely digital workflow involved the following processes. The defective tooth was scanned with an intraoral scanner (CS3500; Carestream Health) before tooth preparation if the tooth morphology or an existing crown was essentially complete and satisfactory. The scan was used as a reference in the restoration design. Tooth shade was selected before tooth preparation by using a shade guide (VITA 3D-Master; VITA Zahnfabrik). Digital photographs were made to record the esthetic characteristics of restorations in the esthetic zone.

The teeth were prepared with medium and fine grit diamond rotary instruments (DIA-BURS; MANI) according to the minimally invasive principle and tooth preparation guidelines of anatomic contour zirconia crowns.[20] For anterior crowns, the labial and proximal reduction were at least 0.5 mm, the lingual reduction was

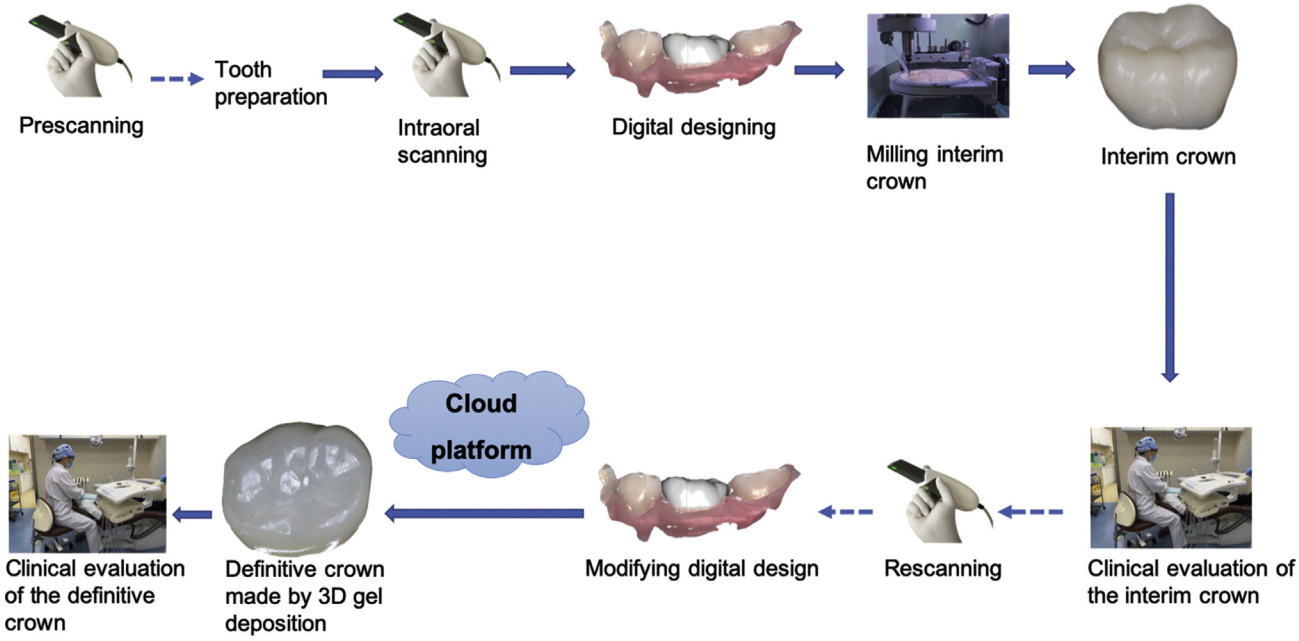

Figure 1. Completely digital prosthodontic workflow. CAD-CAM interim crown used to verify digital design by clinical evaluation and definitive self-glazed zirconia crown produced through additive 3D gel deposition process. CAD-CAM, computer-aided design and computer-aided manufacturing.

Figure 2. Maxillary left first premolar prepared according to tooth preparation principles.

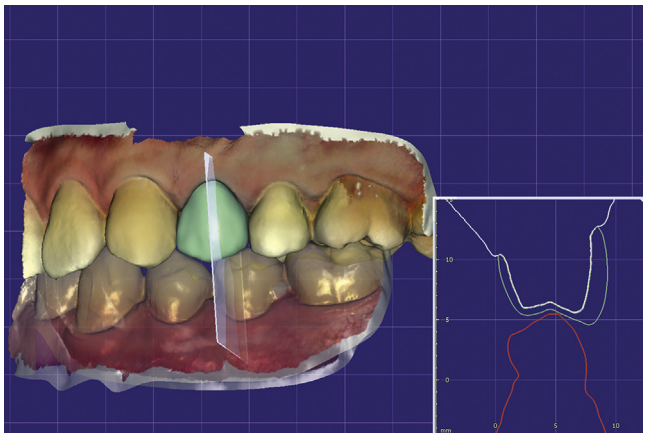

Figure 3. Digital design of interim crown. Design interface included sectional view of dentition showing thickness and morphology of crown at different areas.



Figure 4. Interim crown made chairside. Procedure controlled locally or remotely.

Figure 5. Clinical evaluation of interim crown for accuracy of design. Interim crown for maxillary left first premolar had good marginal adaption and proximal contact. However, height of buccal cusp and mesial marginal ridge, and convexity in cervical third deficient. Design file modified accordingly.

at least 0.7 mm, and the incisal reduction was 0.5 to 1.0 mm. For posterior crowns, the axial reduction was at least 0.5 mm, and the occlusal reduction was at least 0.8 mm. Incremental tooth preparation was needed when the abutment tooth was discolored.[21] The taper was controlled at 2 to 5 degrees with a knife or light chamfer edge in a supragingival location or located to the crest of the free gingival margin.[22,23] Single-cord or double-cord gingival displacement was performed according to the depth of the gingival crevice after tooth preparation (Fig. 2).

A digital cast was obtained by intraoral scanning, and the preparation quality was reevaluated. An interim crown was designed by using a design software program (exocad; exocad GmbH). The cement space was set at 25 μm, the marginal gap at 20 μm, and the default proximal contact to -10 μm (Fig. 3). The design file was sent to a chairside milling machine (Ardenta CS100-5W; ARIX CNC MACHINES CO, LTD), and the interim crown was milled from denture resin (PMMA Disk; YAMAHACHI DENTAL MFG., CO) (Fig. 4). The seating, morphology, occlusion, marginal adaption, and proximal contacts of the interim crown were clinically evaluated (Fig. 5). If the interim crown was acceptable, the design file was directly transferred to the manufacturing center through a cloud platform. If adjustment was needed, the design file was modified accordingly or replaced by rescanning the adjusted interim crown. The interim crown was then cemented (Zinc polycarboxylate cement; ChangShu ShangChi Dental Materials Co, Ltd).

The zirconia crowns were produced by using an additive 3D gel deposition technique. Assessment of the digital fit of the definitive restoration and the design file was used for quality inspection, and the maximum error was set as 60 μm (Fig. 6).

The zirconia crowns were returned and clinically evaluated (Fig. 7). Adjustment was done as necessary to

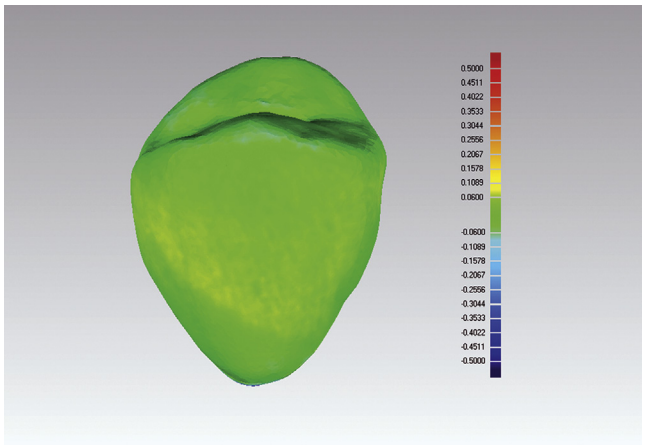

Figure 6. Digital quality inspection by fitting definitive crown of maxillary left first premolar with verified design file. Maximum error within 60 μm and definitive crown determined as qualified.

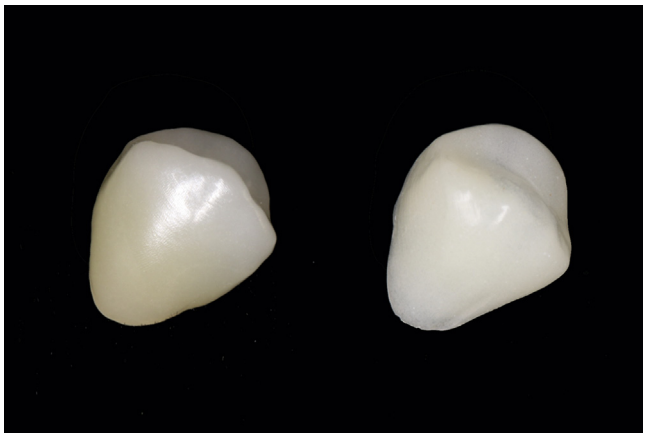

Figure 7. Monolithic zirconia crown made according to modified design (left) and original interim resin crown (right) of maxillary left first premolar. Definitive crown matched morphology with individual color gradient appearance.

achieve appropriate seating, morphology, occlusion, and proximal contact. The extent of adjustment was recorded. The results were divided into zero adjustment, minimal adjustment (less than 5 adjustments, with less than 3 seconds each), and unacceptable (a large amount of adjustment, or those that needed additions, such as for a deficient proximal contact). Adjustment was performed by using an extra fine grit diamond rotary instrument (DIA-BURS; MANI) with water cooling.

Color match and marginal adaption were evaluated according to the modified US Public Health Service (USPHS) criteria.[24] The crowns which were rated as Charlie for color match or Bravo or Charlie for marginal adaption were determined to be unacceptable and were remade. Digital photographs and an updated color selection result were provided for crowns with an unacceptable color match. Acceptable crowns were cemented with a resin modified glass-ionomer cement (RelyX Luting2; 3M ESPE) (Fig. 8).

Figure 8. Postoperative intraoral view. Monolithic zirconia crown of maxillary left first premolar achieved satisfactory outcomes.

RESULTS

A total of 229 zirconia crowns were placed in 177 participants (113 women, 64 men) with the completely digital workflow between 2016 and 2019. Sixty-two crowns (27.1%) were placed in the anterior region and 167 crowns (72.9%) in the posterior region. One hundred thirty-three crowns (58.1%) were placed in the maxilla and 96 crowns (41.9%) in the mandible. Distribution of the crowns is listed in Table 1.

The rate of zero adjustment, minimal adjustment, and unacceptable was 93.0% (213/229), 4.8% (11/229), and 2.2% (5/229), respectively. Of the 5 unacceptable crowns that could not meet the clinical requirements through slight adjustment, 3 had a deficient proximal contact, 1 had a deficient incisal length, and 1 was not in occlusion (Table 2).

The remaining 224 crowns had a marginal adaption rated as Alfa, that is the explorer could smoothly cross the margin without tripping, and no gap or overhang between the crown and the abutment tooth could be detected. In terms of color match, 91.5% (205/224) were rated as Alfa with satisfactory appearance, 6.3% (14/224) were rated as Bravo with acceptable appearance, and 2.2% (5/224) were rated as Charlie with unacceptable appearance. Of the crowns with unacceptable color mismatch, 1 reflected the underlying tooth color, 2 had an excessively yellow color, and 2 were incompatible with the adjacent teeth or prosthesis (Table 3).

DISCUSSION

The hypothesis of this study that the monolithic zirconia crowns fabricated with the completely digital workflow would achieve satisfactory clinical performance was accepted. High zero-adjustment rate (93.0%), good

Table 1. Distribution of 229 self-glazed zirconia crowns

	Central Incisor		Lateral Incisor		Canine		First Premolar		Second Premolar		First Molar		Second Molar		Third Molar	
Position	M	F	M	F	M	F	M	F	M	F	M	F	M	F	M	F
Maxillary	6	25	5	18	1	4	4	9	11	9	13	19	2	7	0	0
Mandibular	1	1	0	0	0	1	4	2	6	18	7	29	12	14	0	1

F, female; M, male.

Table 2. Clinical efficiency of 229 zirconia crowns fabricated with completely digital prosthodontic workflow

Year	Total Number	Zero Adjustment Number (Rate, %)	Minimal Adjustment Number (Rate, %)	Unacceptable Number (Rate, %)	Reasons for Unacceptable Crowns
2016	20	16 (80.0)	3 (15.0)	1 (5.0)	Mandibular left second premolar crown had deficient mesial proximal contact, since slightly mobile adjacent tooth displaced by interim crown.
2017	58	53 (91.4)	4 (6.9)	1 (1.7)	Mandibular left second molar crown had deficient mesial proximal contact. Tooth had long clinical crown and definitive crown had mesial seating interference. After adjustment proximal contact deficient.
2018	88	83 (94.3)	3 (3.4)	2 (2.3)	Mandibular right first molar crown had deficient mesial proximal contact, since slightly mobile adjacent tooth displaced by interim crown. Maxillary left incisor crown had deficient incisal length, different from the interim crown. Probably from manufacturing and quality inspection errors.
2019	63	61 (96.8)	1 (1.6)	1 (1.6)	Mandibular left second premolar crown not in occlusion, and different from interim crown. Possibly from manufacturing and quality inspection errors.
Total	229	213 (93.0)	11 (4.8)	5 (2.2)	––

Table 3. Clinical evaluation of 224 zirconia crowns according to modified USPHS criteria

Year	Total Number	Marginal Adaption			Color Match			Reasons for Unacceptable Crowns
		Alfa	Bravo	Charlie	Alfa	Bravo	Charlie	
2016	19	19	0	0	16	3	0	––
2017	57	57	0	0	52	4	1	Maxillary left lateral incisor severely discolored after pulp necrosis. Definitive crown with mild color masking ineffective, and increased color masking applied.
2018	86	86	0	0	80	6	0	––
2019	62	62	0	0	57	1	4	Maxillary right lateral incisor severely discolored after pulp necrosis. Crown with high color masking effective but translucency not compatible with adjacent teeth. Crown remade with increased translucency. Color and translucency of maxillary right lateral incisor crown not compatible with adjacent veneered zirconia prosthesis. Maxillary right and left incisor crowns had excessively yellow color.
Total	224	224	0	0	205	14	5	––

USPHS, United States Public Health Service.

marginal adaption (100%), and esthetic appearance (91.5%) of the restorations verified the effectiveness of this completely digital workflow. By verifying the accuracy of the digital design with CAD-CAM interim crowns intraorally and applying the 3D gel deposition process, the precision of the definitive crowns and the general clinical efficiency were improved. With familiarity and the technical development of this completely digital workflow, the zero-adjustment rate gradually increased from 80.0% in 2016 to 96.8% in 2019. Besides improving clinical efficiency, zero adjustment benefits the long-term success of the restorations by eliminating grinding induced defects. Moreover, the gradient structure of self-glazed zirconia restorations could be protected to simulate the structure and function of natural teeth.

Consistent with the present finding, other studies have reported on the advantages of a completely digital workflow in producing restorations, although the processes of the digital workflow have been different. Joda and Bragger[25] reported that implant-supported crowns fabricated with a completely digital workflow did not require clinical adjustment (20/20, 100%), while some crowns fabricated with mixed analog-digital workflow needed proximal adjustment (8/20, 40%) or occlusal adjustment (6/20, 30%). Zhang et al[26] conducted a quantitative clinical analysis and reported that the median maximum vertical adjustment in the completely digital workflow group (237 ±112 μm) was significantly less than that of the partial digital workflow group (485 ±195 μm).

In the present study, 2 unacceptable crowns with clear differences from the interim crowns might have been from manufacturing and quality inspection errors. For 2 of the 3 crowns with a deficient proximal contact, the adjacent tooth had migrated. The other crown with a deficient

proximal contact was used to restore a tooth with a long clinical crown. The interim crown could be placed successfully, but the zirconia one could not. Thus, the different elastic property of the interim crown and zirconia crown should be considered when verifying the design.

The esthetic outcome of most definitive crowns in the present study was satisfactory, although this can be challenging with monolithic zirconia restorations.[27,28] Cui et al[12] reported that anatomic contour zirconia crowns fabricated with the 3D gel deposition process matched adjacent teeth better and had excellent esthetics in terms of color and translucency gradient. In the present study, tooth color was selected traditionally from shade guides, which may have influenced the result. Digital colorimeters have been reported to quantify the tooth color with higher accuracy than the traditional shade guide, but the result can be affected by different conditions, including the surface texture and anatomic variations of natural teeth, plaque and saliva, and measurement procedures such as the pressure and angle when the contact tip was applied.[29-31] Colorimeters need to be developed and then be integrated into the advanced completely digital workflow.

Limitations of this retrospective study included the lack of a control group, quantitative evaluations, and follow-up evaluations. Therefore, randomized controlled trials and clinical follow-up studies are necessary to evaluate this completely digital workflow and the long-term performance of the monolithic zirconia crowns provided.

CONCLUSIONS

Based on the findings of this clinical study, the following conclusion was drawn:

1. Self-glazed monolithic zirconia crowns fabricated with the completely digital workflow provided a straightforward prosthodontic strategy and achieved efficient and satisfactory clinical performance.

REFERENCES

1. Duret F, Preston JD. CAD/CAM imaging in dentistry. Curr Opin Dent 1991;1:150-4.
2. Christensen GJ. Will digital impressions eliminate the current problems with conventional impressions? J Am Dent Assoc 2008;139:761-3.
3. Yuzbasioglu E, Kurt H, Turunc R, Bilir H. Comparison of digital and conventional impression techniques: evaluation of patients' perception, treatment comfort, effectiveness and clinical outcomes. BMC Oral Health 2014;14:10.
4. Abdullah AO, Pollington S, Liu Y. Comparison between direct chairside and digitally fabricated temporary crowns. Dent Mater J 2018;37:957-63.
5. Luo XP, Zhang L. Effect of veneering techniques on color and translucency of Y-TZP. J Prosthodont 2010;19:465-70.
6. Sailer I, Makarov NA, Thoma DS, Zwahlen M, Pjetursson BE. All-ceramic or metal-ceramic tooth-supported fixed dental prostheses (FDPs)? A systematic review of the survival and complication rates. Part I: Single crowns (SCs). Dent Mater 2015;31:603-23.
7. Bai YY, Zhao J, Si WJ, Wang XZ. Two-body wear performance of dental colored zirconia after different surface treatments. J Prosthet Dent 2016;116:584-90.
8. Zhao J, Zhang K, Liu YH, Shen ZJ. Effect of multistep processing technique on the formation of micro-defects and residual stresses in zirconia dental restorations. J Prosthodont 2014;23:206-12.
9. Kosmac T, Oblak C, Jevnikar P, Funduk N, Marion L. The effect of surface grinding and sandblasting on flexural strength and reliability of Y-TZP zirconia ceramic. Dent Mater 1999;15:426-33.
10. Tidehag P, Shen ZJ. Digital dentistry calls the change of ceramics and ceramic processes. Adv Appl Ceram 2019;118:83-90.
11. Li R, Chen H, Wang Y, Zhou YS, Shen ZJ, Sun YC. Three-dimensional trueness and margin quality of monolithic zirconia restorations fabricated by additive 3D gel deposition. J Prosthodont Res 2020;64:478-84.
12. Cui XY, Shen ZJ, Wang XZ. Esthetic appearances of anatomic contour zirconia crowns made by additive wet deposition and subtractive dry milling: A self-controlled clinical trial. J Prosthet Dent 2020;123:442-8.
13. Liu YH, Wang Y, Wang DZ, Ma J, Liu LF, Shen ZJ. Self-glazed zirconia reducing the wear to tooth enamel. J Eur Ceram Soc 2016;36:2889-94.
14. Ren W, Du FL, Shen ZJ, Wu Z, Yang XC, Xu G, et al. The workflows of a novel self-glazed zirconia for dental prostheses fabrication: case reports. Adv Appl Ceram 2018;117:406-13.
15. Wu JW, Huang Z, Yang L, Li YJ, Liang TT, Jiang QZ, et al. The application of net-shape-formed self-glazed zirconia prostheses via a complete digital workflow in oral implant and restoration: a clinical case report. Adv Appl Ceram 2019;118:309-12.
16. Wu Z, Shi AD, Liang Q, Liu TT, Huang JY, Shen ZJ. Aesthetic restoration of anterior teeth with monolithic self-glazed zirconia crowns via a completely digital workflow: a clinical case report. Adv Appl Ceram 2020;119:291-6.
17. Ren W, Yang L, Du FL, Huang JY, Huang Z, Liang TT, et al. Chipped porcelain-fused-to-metal restoration repaired by the novel self-glazed zirconia veneering with a digital workflow. Adv Appl Ceram 2020;119:317-22.
18. Huang Z, Huang JY, Li CX, Shi AD, Wu JW, Ren W, et al. The application of 3D printed self-glazed zirconia for full-mouth rehabilitation in a patient with severely worn dentition: a case report. Adv Appl Ceram 2020;119:305-11.
19. Wu JW, Huang JY, Li CX, Liang TT, Li FY, Huang Z, et al. The bridge restoration made by self-glazed zirconia with a digital processes. Adv Appl Ceram 2020;119:312-6.
20. Goodacre CJ, Campagni WV, Aquilino SA. Tooth preparations for complete crowns: an art form based on scientific principles. J Prosthet Dent 2001;85:363-76.
21. Wang F, Takahashi H, Iwasaki N. Translucency of dental ceramics with different thicknesses. J Prosthet Dent 2013;110:14-20.
22. Poggio CE, Dosoli R, Ercoli C. A retrospective analysis of 102 zirconia single crowns with knife-edge margins. J Prosthet Dent 2012;107:316-21.
23. Reich S, Petschelt A, Lohbauer U. The effect of finish line preparation and layer thickness on the failure load and fractography of ZrO_2 copings. J Prosthet Dent 2008;99:369-76.
24. Cvar JF, Ryge G. Reprint of Criteria for the clinical evaluation of dental restorative materials. Clin Oral Investig 2005;9:215-32.
25. Joda T, Bragger U. Time-efficiency analysis of the treatment with monolithic implant crowns in a digital workflow: a randomized controlled trial. Clin Oral Implants Res 2016;27:1401-6.
26. Zhang YF, Tian JH, Wei DH, Di P, Lin Y. Quantitative clinical adjustment analysis of posterior single implant crown in a chairside digital workflow: A randomized controlled trial. Clin Oral Implants Res 2019;30:1059-66.
27. Batson ER, Cooper LF, Duqum I, Mendonça G. Clinical outcomes of three different crown systems with CAD/CAM technology. J Prosthet Dent 2014;112:770-7.
28. Konstantinidis I, Trikka D, Gasparatos S, Mitsias ME. Clinical outcomes of monolithic zirconia crowns with CAD/CAM technology. A 1-year follow-up prospective clinical study of 65 patients. Int J Environ Res Public Health 2018;15:2523.
29. Preethi Suganya S, Manimaran P, Saisadan D, Dhinesh Kumar C, Abirami D, Monnica V. Spectrophotometric evaluation of shade selection with digital and visual methods. J Pharm Bioallied Sci 2020;12:S319-23.
30. Kim-Pusateri S, Brewer JD, Davis EL, Wee AG. Reliability and accuracy of four dental shade-matching devices. J Prosthet Dent 2009;101:193-9.
31. Tung FF, Goldstein GR, Jang S, Hittelman E. The repeatability of an intraoral dental colorimeter. J Prosthet Dent 2002;88:585-90.

Corresponding author:
Dr Yuanna Zheng
School of Stomatology, Zhejiang Chinese Medical University
548 Binwen Rd Box 97
Hangzhou, 310053
PR CHINA
Email: zyn218@126.com

Acknowledgments
The authors thank Mrs Yaqi Lu for her participation in the intraoral scanning and restoration design and Mr Mingjie Wang for his contribution in the collection of clinical data.

CRediT authorship contribution statement
Lifang Wu: Writing - original draft, Formal analysis, Software. **Zhe Sun:** Investigation, Data curation. **Jing Zhao:** Writing - review & editing, Supervision. **Yuanna Zheng:** Conceptualization, Resources, Writing - review & editing.

https://doi.org/10.1016/j.prosdent.2021.01.018